2025 21st International Symposium on Biomedical Image Processing and Analysis (SIPAIM) | 979-8-3315-5456-9/25/$31.00 ©2025 IEEE | DOI: 10.1109/SIPAIM67325.2025.11283294

DTI versus NODDI White Matter Microstructural Biomarkers of Alzheimer's Disease

Kenny Liou[1], Sophia I. Thomopoulos[1], Hannah Yoo[1], Yuhan Shuai[1], Sasha Chehrzadeh[1], Arvin Arani[2], Bret Borowski[2], Robert I. Reid[2], Clifford R. Jack, Jr.[2], Michael W. Weiner[3], Neda Jahanshad[1], Paul M. Thompson[1], Talia M. Nir[1]; Alzheimer's Disease Neuroimaging Initiative
Kenny.Liou@loni.usc.edu
[1]*Imaging Genetics Center, Mark and Mary Stevens Neuroimaging and Informatics Institute, Keck School of Medicine, University of Southern California, Marina del Rey, CA, USA*
[2]*Department of Radiology, Mayo Clinic, Rochester, Minnesota, USA*
[3]*Department of Radiology, School of Medicine, University of California, San Francisco, CA, USA*

***Abstract*—Diffusion MRI (dMRI) is a powerful tool to assess white matter (WM) microstructural abnormalities in Alzheimer's disease (AD). The fourth phase of the Alzheimer's Disease Neuroimaging Initiative (ADNI) now includes multiple multishell dMRI protocols, enabling both traditional and advanced dMRI model analyses. There is a need to evaluate whether multishell data offer deeper insights into WM pathology in AD than more widely available single-shell data by overcoming single-shell model limitations. Here, we fit single-shell DTI and multishell NODDI to dMRI data from 533 ADNI3/4 participants to assess their association with key clinical indicators of AD such as cognitive impairment, amyloid-beta and tau PET burden. Overall, we found that NODDI showed comparable associations with cognitive impairment and tau pathology, but somewhat stronger relationships with amyloid pathology.**

Keywords—dMRI, Alzheimer's Disease, DTI, NODDI, ADNI

I. INTRODUCTION

Diffusion MRI (dMRI) is a powerful imaging technique for evaluating brain tissue, providing valuable insights into white matter (WM) microstructure. Its association with WM abnormalities has made it a key tool in the study of neurodegenerative diseases such as Alzheimer's disease (AD) [1]. It is therefore critical to understand the utility of dMRI as a sensitive biomarker for key AD pathology, including amyloid-beta (Aβ) and tau, in addition to downstream cognitive impairment.

Historically, single-shell dMRI have been most commonly used due to their generally shorter scan times and less demanding hardware requirements. This has led to the widespread use of diffusion tensor imaging (DTI) [2], a model that characterizes Gaussian diffusion from single-shell acquisitions. Numerous DTI studies have identified AD-related WM abnormalities, such as greater diffusivity and reduced anisotropy in key brain regions like the corpus callosum, cingulum bundle, and fornix, particularly with respect to degree of clinical impairment [3,4]. However, DTI has significant limitations. It cannot accurately model complex fiber architectures, such as crossing fibers, and often lack biological specificity, making it difficult to precisely link observed changes to underlying tissue properties [5]. Multishell dMRI protocols address these limitations by capturing both Gaussian and non-Gaussian diffusion signals, allowing finer characterization of WM. In particular, biophysical multishell models, such as neurite orientation dispersion and density imaging (NODDI) [6], can parse signal contributions from various tissue compartments including the intracellular compartment and free water. There is a need to evaluate whether multishell data offers deeper insights into WM alterations in AD by moving beyond the limitations of DTI, particularly for detecting subtle effects associated with early amyloid and tau pathology; however, such investigations remain scarce.

The Alzheimer's Disease Neuroimaging Initiative (ADNI) is an ongoing large-scale, longitudinal, multicenter study dedicated to identifying brain imaging, clinical, cognitive, and molecular biomarkers of AD and aging [7]. Now in its fourth phase, ADNI has expanded from a single multishell protocol to multiple multishell dMRI protocols across GE, Philips and Siemens scanners, enabling both traditional and advanced dMRI model analyses. In this study, we compared the ability of ADNI DTI and NODDI WM measures to detect associations with several key AD indicators: Aβ burden, tau pathology, and clinical measures of cognitive impairment. We also assessed whether sex moderates these effects. This is important given females have a higher prevalence of AD than males and exhibit distinct pathological and cognitive profiles [8, 9]. We hypothesized that NODDI-derived WM measures would provide better biological specificity, stronger associations with AD indicators, and that these effects would be more pronounced in females than in males.

II. METHODS

A. Subject and Image Acquisition

Baseline 3 T T1-weighted (T1w) MRI and multishell dMRI data were downloaded from the ADNI database (https://ida.loni.usc.edu/). In total, we analyzed dMRI data from 533 participants across ADNI3/4: 341 cognitively normal elderly controls (CN), 149 mild cognitive impairment cases (MCI), and 43 dementia cases (**Table 1**). All participants were scanned with one of four ADNI3/4 multishell dMRI protocols (**Table 2**). Key clinical indicators of AD, specifically Clinical Dementia Rating sum-of-boxes (CDR-sob; N=529) [10], Aβ-PET centiloids (CLs; N=213) [11], and tau-PET standardized value uptake ratios (SUVRs; N=186) [12], were obtained when available. Cortical Aβ-PET (18F-florbetaben, 18F-florbetapir, 18F-NAV4694) CLs were derived using methods described in [13]. Tau-PET (18F-flortaucipir) burden was defined using the medial

Authorized licensed use limited to: OAKLAND UNIVERSITY. Downloaded on February 15,2026 at 22:22:28 UTC from IEEE Xplore. Restrictions apply.

Table 1. Subject Demographic and Clinical Information.

Diagnosis (N)	Age (yrs)	Male (N)	CDR-sob	Aβ-PET (CL)	Tau-PET (SUVR)	Education (yrs)	Self-Reported Race* (N)	Ethnicity+ (N Hispanic)
CN (341)	70.0±8.5	122	0.05±0.2	16.5±28.6	1.2±0.2	16.4±2.5	203 White, 88 Black, 50 Other	39 Hispanic
MCI (149)	73.2±8.1	69	1.5±1.1	46.9±49.4	1.6±0.7	15.8±2.5	103 White, 27 Black, 19 Other	9 Hispanic
Dementia (43)	76.7±6.9	20	4.3±1.8	95.2±35.6	2.1±0.4	15.5±3.0	30 White, 9 Black, 4 Other	1 Hispanic

*'Other' is defined as Asian, American Indian, Alaskan Native, or mixed race. +Ethnicity is defined here as Hispanic or non-Hispanic.

temporal SUVR normalized using measures from the inferior cerebellar gray matter.

B. Image Preprocessing

ADNI3 dMRI were preprocessed as in [14]. As in ADNI3, all dMRI were denoised using principal component analysis (PCA) techniques [15,16] and corrected for Gibbs ringing [17]. For ADNI4 only, susceptibility distortions were corrected using FSL's *topup* [18] using concatenated anterior-posterior (AP) and posterior-anterior (PA) scans. The concatenated AP-PA images were carried through the remaining preprocessing and analysis. The ADNI3 S127 protocol lacked AP scans and were distortion-corrected using Synb0-DisCo [19]. GE multishell scans were excluded from *topup* since distortions were corrected in-scanner. Extra-cerebral tissue was removed and eddy correction performed with FSL's *eddy* tool, including outlier and slice timing corrections [20, 21, 22]. The resulting dMRI were corrected for B1 field inhomogeneities then linearly and nonlinearly registered to the subjects' respective T1w (preprocessed with the standard FreeSurfer pipeline [23]) using ANTs; the linear registration was subsequently inverted to bring the T1w to the native DWI space [14]. All dMRI and T1w images were visually checked for quality assurance.

Table 2. Available ADNI3 and ADNI4 multishell acquisition protocols. All dMRI were acquired with an isotropic 2x2x2 mm^3 voxel size. GE127 dMRI were zero-padded in *k*-space during acquisition to a 0.9x0.9x2 mm^3 voxel size.

Protocol	Scanner Vendor: Model(s)	Volumes		Matrix
		PA	AP	
GE127	GE: Premier 29.1 48CH Advanced & MR750 29.1 32Ch Nova Advanced	13 b_0	NA	256x256
		6 b=500 s/mm^2		
		48 b=1000 s/mm^2		
		60 b=2000 s/mm^2		
		Total: 127		
P100	Philips: Advanced 5 6x	9 b_0	1 b_0	128x126
		6 b=500 s/mm^2		
		38 b=1000 s/mm^2	6 b=1000 s/mm^2	
		47 b=2000 s/mm^2		
		Total: 100	*Total: 7*	
S100	Siemens: Skyra VE11C & Vida XA20	9 b_0	1 b_0	116x116
		6 b=500 s/mm^2		
		38 b=1000 s/mm^2	12 b=1000 s/mm^2	
		47 b=2000 s/mm^2		
		Total: 100	*Total: 13*	
S127*	Siemens: Advanced Prisma VE11C	13 b_0	1 b_0	116x116
		6 b=500 s/mm^2		
		48 b=1000 s/mm^2	6 b=1000 s/mm^2	
		60 b=2000 s/mm^2		
		Total: 127	*Total: 7*	

*S127: ADNI3 lacks AP scans; ADNI4 includes AP scans.

C. DTI and NODDI Extraction

DTI was fit on the subset of b_0 and b=1000 s/mm^2 dMRI volumes and NODDI was fit across all volumes. DTI was computed with FSL using weighted least squares and NODDI was computed using DmiPy [24]. Fractional anisotropy (FA), mean (MD), axial (AxD), and radial diffusivity (RD) maps were derived from DTI. Intracellular volume fraction (ICVF), isotropic volume fraction (ISOVF), and orientation dispersion index (ODI) maps were extracted from NODDI. As in [14], the JHU ICBM-DTI-81 [25] atlas FA was warped to each subject's FA. The transformations were applied to stereotaxic JHU WM atlas labels (JHU MNI single subject WMPM1) [25] using nearest neighbor interpolation. Mean DTI and NODDI measures were extracted from 31 WM regions of interest (ROIs), averaged across the left and right hemispheres (**Table 3**).

Table 3. Index of 31 JHU atlas WM ROIs.

CST	Corticospinal tract	**ML**	Medial lemniscus
IC	Internal capsule	**CP**	Cerebral peduncle
AIC	Ant. limb of IC	**ICP**	Inf. CP
PLIC	Post. limb of IC	**MCP**	Middle CP
RLIC	Retrolenticular part of IC	**PCT**	Pontine crossing tract
PTR	Post. thalamic radiation		
CR	Corona radiata	**SCP**	Sup. CP
ACR	Ant. CR	**SS**	Sagittal stratum
SCR	Sup. CR	**FxST**	Fornix (crus)/*Stria terminalis*
PCR	Post. CR		
CGC	Cingulum (cingulate)	**UNC**	Uncinate fasciculus
CGH	Cingulum (hippocampal)	**TAP**	Tapetum
EC	External capsule	**CC**	Full corpus callosum
Fx	Fornix	**GCC**	Genu of CC
SLF	Sup. longitudinal fasciculus	**BCC**	Body of CC
		SCC	Splenium of CC
SFO	Sup. fronto-occipital fasciculus	**FullWM**	Full white matter

D. Statistical Analyses

Linear mixed effects models were used to assess associations between regional dMRI measures and key AD indicators: (1) CDR-sob, (2) an MCI versus CN diagnosis, (3) Aβ-PET CLs, and (4) tau-PET SUVRs. We also tested whether sex moderated the effect between AD indicators and dMRI measures. Fixed effects covariates included age, sex, age-by-sex interactions, education, self-reported race, and ethnicity. We additionally covaried for diagnosis in Aβ and tau analyses. Across analyses, dMRI protocol and preprocessing scheme was modeled as a random effect. Effect sizes were

Authorized licensed use limited to: OAKLAND UNIVERSITY. Downloaded on February 15,2026 at 22:22:28 UTC from IEEE Xplore. Restrictions apply.

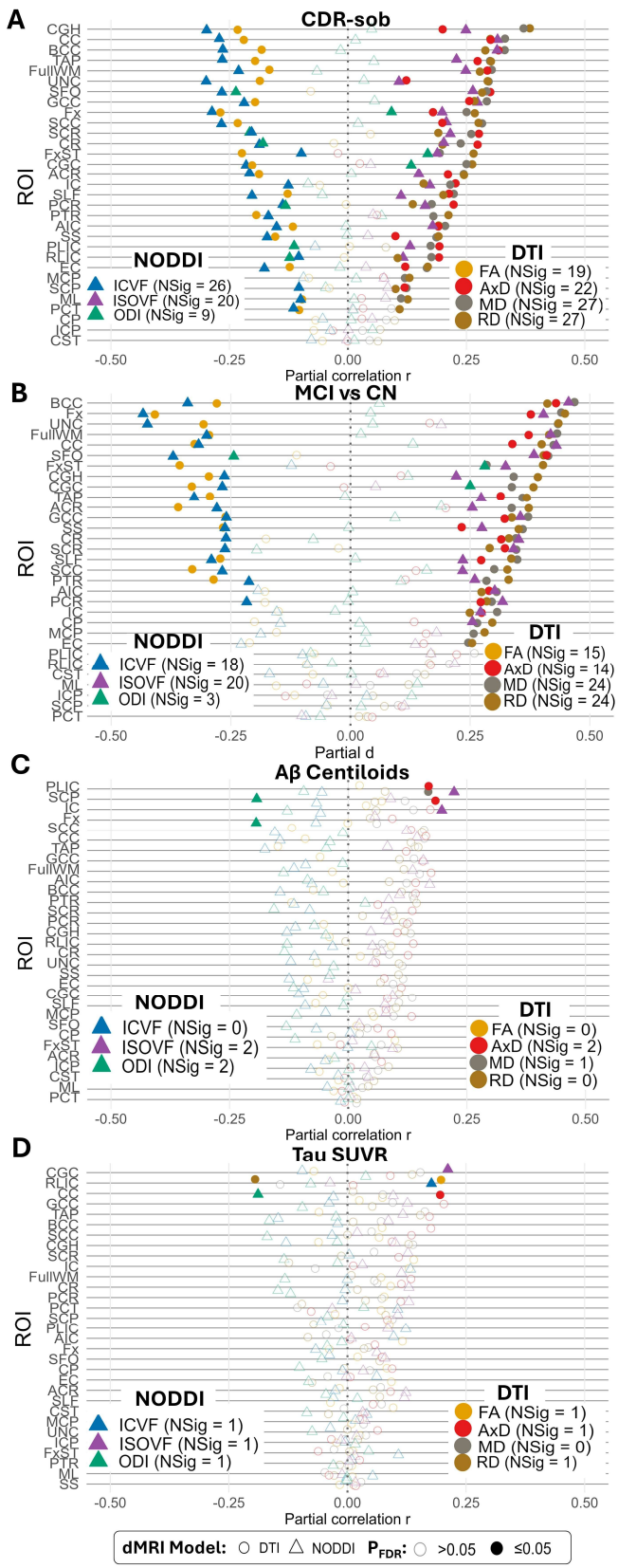

Figure 1. Effect sizes for associations between regional DTI and NODDI measures and (**A**) CDR-sob, (**B**) MCI diagnosis, (**C**) Aβ-PET CLs, and (**D**) tau-PET SUVRs. Significant associations are opaque (P_{FDR}<0.05).

estimated using partial *d* and partial correlation *r* for categorical and continuous AD indicators, respectively. The false discovery rate (FDR) procedure [26] was used to correct for multiple comparisons across 31 ROIs.

III. Results

A. DTI and NODDI Associations with AD Outcomes

Lower FA and ICVF, and higher AxD, MD, RD, and ISOVF were widely associated with greater cognitive impairment (i.e., higher CDR-sob and a MCI diagnosis; P_{FDR}<0.05; **Fig. 1A, B**). While effects were detected globally in the Full WM, the strongest effects localized to the CC and the limbic tracts including the CGH, UNC, and Fx. Fewer associations were seen with ODI. Greater Aβ burden was linked to higher AxD, MD, ISOVF, and lower ODI across the IC (ISOVF), SCP (AxD, ODI), and Fx (ODI) (**Fig. 1C**). Greater tau burden was associated with higher AxD in the CC, FA and ICVF in the RLIC, and ISOVF in the CGC. Tau was also associated with lower RD in the RLIC and ODI in the CC (**Fig. 1D**).

B. Sex-Specific Patterns in DTI and NODDI measures

Few sex-by-cognitive impairment interactions were found: no CDR-by-sex interactions were detected and only 3 dMRI ROI measures showed significant MCI-by-sex interactions (**Table 3**). Males showed higher AxD and MD in the EC and higher AxD in the UNC compared to females. In contrast, a greater number of sex-by-PET pathology interactions were detected (**Table 3**). Again, with greater Aβ and tau, overall males showed greater diffusivity and ISOVF, and lower FA, ICVF and ODI compared to females. As an example of sex-by-PET trends, scatter plots of FA in the cingulum illustrate that males showed a steeper decline in anisotropy compared to females with increasing Aβ and tau load (**Fig 2**).

Table 3. Number of ROIs showing significant sex interactions per AD indicator and dMRI measure (P_{FDR}<0.05).

Test	Total	DTI				NODDI		
		FA	MD	RD	AxD	ICVF	ISOVF	ODI
CDR-sob	0	0	0	0	0	0	0	0
CN vs MCI	3	0	1	0	2	0	0	0
Aβ-PET	20	2	4	5	2	2	4	1
Tau-PET	23	6	4	5	1	1	4	2

IV. Discussion

Overall, NODDI showed comparable associations with measures of clinical impairment and tau pathology. The largest effects were found in limbic and temporal lobe regions that are vulnerable in AD, particularly with DTI diffusivity and NODDI ISOVF measures, in line with previous reports [27]. In contrast, NODDI ISOVF and ODI were marginally more correlated with Aβ burden than DTI measures, not only in limbic tracts like the Fx, but the largest effects were found in the PLIC. While lower DTI FA and increased diffusivity may indicate nonspecific WM deterioration, NODDI measures can provide more insight. Lower ICVF and ODI, and higher ISOVF suggest these effects may be driven by neuronal loss, reduced tissue complexity, and greater free water which may indicate inflammation/edema, respectively.

Authorized licensed use limited to: OAKLAND UNIVERSITY. Downloaded on February 15,2026 at 22:22:28 UTC from IEEE Xplore. Restrictions apply.

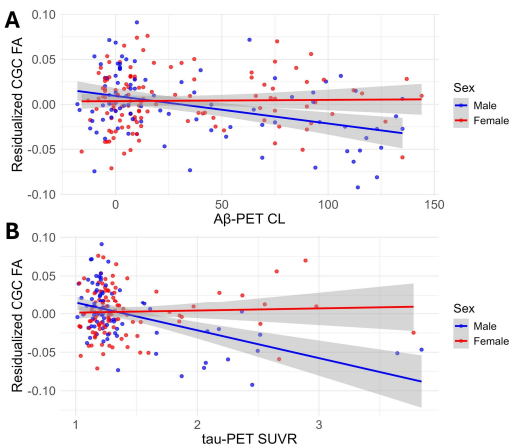

Figure 2. Cingulum (CGC) FA residuals illustrate that males showed a steeper decline in anisotropy compared to females with increasing (**A**) Aβ and (**B**) tau load.

We found a greater number of sex differences in amyloid and tau pathological markers compared to cognitive impairment metrics, suggesting that sex-related biological factors may influence disease pathology before detectable cognitive decline. Interestingly, males showed greater disease effects than females, and not *vice versa*. It is possible that the complex interplay of genetic, hormonal (e.g., estrogen decline during menopause), and immunological factors that influence disease risk and progression in females [26] may increase inter-individual variability and obscure group-level effects. Disentangling these overlapping influences is critical for characterizing sex-specific disease trajectories and for informing the development of targeted diagnostic and therapeutic strategies.

As more ADNI4 multishell dMRI data become available, future work will investigate potential confounders of sex-specific group-level effects to unpack the complex sex-related patterns observed in AD. We will also compare multishell models that do not parse the signal, such as mean apparent propagator (MAP) MRI [28], with DTI and NODDI and refine spatial localization using along-tract analyses. Integration of richer WM features across models could enhance detection of cognitive impairment, Aβ burden, and tau pathology in AD research.

Acknowledgments

This work was supported by AARG-23-1149996, R01AG058854, R01AG087513, RF1AG057892, U01AG068057, U19AG024904, S10OD032285.

References

[1] C. Andica et al., “MR Biomarkers of Degenerative Brain Disorders Derived From Diffusion Imaging,” J. Magn. Reson. Imaging, vol. 52, no. 6, pp. 1620–1636, 2020.

[2] P. J. Basser et al., “MR diffusion tensor spectroscopy and imaging,” Biophys. J., vol. 66, no. 1, pp. 259–267, Jan. 1994.

[3] T. M. Nir et al., “Effectiveness of regional DTI measures in distinguishing Alzheimer’s disease, MCI, and normal aging,” NeuroImage Clin., vol. 3, pp. 180–195, Jul. 2013.

[4] A. Zavaliangos-Petropulu et al., “Diffusion MRI Indices and Their Relation to Cognitive Impairment in Brain Aging: The Updated Multi-protocol Approach in ADNI3,” Front. Neuroinformatics, vol. 13, p. 2, Feb. 2019.

[5] K. Oishi et al., “DTI Analyses and Clinical Applications in Alzheimer’s Disease,” J. Alzheimers Dis., vol. 26, no. Suppl 3, pp. 287–296, 2011.

[6] H. Zhang et al., “NODDI: practical in vivo neurite orientation dispersion and density imaging of the human brain,” NeuroImage, vol. 61, no. 4, pp. 1000–1016, Jul. 2012.

[7] R. C. Petersen et al., “Alzheimer’s Disease Neuroimaging Initiative (ADNI),” Neurology, vol. 74, no. 3, pp. 201–209, Jan. 2010.

[8] N. T. Aggarwal and M. M. Mielke, “Sex Differences in Alzheimer’s Disease,” Neurol. Clin., vol. 41, no. 2, pp. 343–358, May 2023.

[9] M. M. Mielke, “Sex and Gender Differences in Alzheimer’s Disease Dementia,” Psychiatr. Times, vol. 35, no. 11, pp. 14–17, Nov. 2018.

[10] L. Berg, “Clinical Dementia Rating (CDR),” Psychopharmacol. Bull., vol. 24, no. 4, pp. 637–639, 1988.

[11] W. E. Klunk et al., “The Centiloid Project: Standardizing Quantitative Amyloid Plaque Estimation by PET,” Alzheimers Dement. J. Alzheimers Assoc., vol. 11, no. 1, pp. 1-15.e4, Jan. 2015.

[12] P. Vemuri et al., “Tau-PET uptake: Regional variation in average SUVR and impact of amyloid deposition,” Alzheimers Dement. Diagn. Assess. Dis. Monit., vol. 6, pp. 21–30, Dec. 2016.

[13] S. M. Landau et al., “Positron emission tomography harmonization in the Alzheimer’s Disease Neuroimaging Initiative: A scalable and rigorous approach to multisite amyloid and tau quantification,” Alzheimers Dement., vol. 21, no. 1, p. e14378, 2025.

[14] S. I. Thomopoulos et al., "Diffusion MRI metrics and their relation to dementia severity: effects of harmonization approaches," in Proc. 17th Int. Symp. Med. Inf. Process. Anal., vol. 12088, Campinas, Brazil, Dec. 2021, pp. 120880K.

[15] Manjón, J. V et al., ‘Diffusion weighted image denoising using overcomplete local PCA.,’ PLoS One 8(9), e73021 (2013).

[16] J. Veraart et al., “Denoising of diffusion MRI using random matrix theory,” NeuroImage, vol. 142, pp. 394–406, Nov. 2016.

[17] E. Kellner et al., “Gibbs-ringing artifact removal based on local subvoxel-shifts,” Magn. Reson. Med., vol. 76, no. 5, pp. 1574–1581, Nov. 2016.

[18] J. L. R. Andersson et al., “How to correct susceptibility distortions in spin-echo echo-planar images: application to diffusion tensor imaging,” NeuroImage, vol. 20, no. 2, pp. 870–888, Oct. 2003.

[19] K. G. Schilling et al., “Synthesized b0 for diffusion distortion correction (Synb0-DisCo),” Magn. Reson. Imaging, vol. 64, pp. 62–70, Dec. 2019.

[20] J. L. R. Andersson and S. N. Sotiropoulos, “An integrated approach to correction for off-resonance effects and subject movement in diffusion MR imaging,” NeuroImage, vol. 125, pp. 1063–1078, Jan. 2016.

[21] J. L. R. Andersson et al., “Incorporating outlier detection and replacement into a non-parametric framework for movement and distortion correction of diffusion MR images,” NeuroImage, vol. 141, pp. 556–572, Nov. 2016.

[22] J. L. R. Andersson et al., “Towards a comprehensive framework for movement and distortion correction of diffusion MR images: Within volume movement,” NeuroImage, vol. 152, pp. 450–466, May 2017.

[23] B. Fischl et al., “Automatically parcellating the human cerebral cortex,” Cereb. Cortex N. Y. N 1991, vol. 14, no. 1, pp. 11–22, Jan. 2004.

[24] R. H. J. Fick et al., “The Dmipy toolbox: Diffusion MRI multi-compartment modeling and microstructure recovery made easy,” Front. Neuroinform., vol. 13, p. 64, Oct. 2019.

[25] S. Mori et al., “Stereotaxic White Matter Atlas Based on Diffusion Tensor Imaging in an ICBM Template,” NeuroImage, vol. 40, no. 2, pp. 570–582, Apr. 2008.

[26] Y. Benjamini and Y. Hochberg, “Controlling the False Discovery Rate: A Practical and Powerful Approach to Multiple Testing,” J. R. Stat. Soc. Ser. B Methodol., vol. 57, no. 1, pp. 289–300, 1995.

[27] C. Lopez-Lee et al., “Mechanisms of sex differences in Alzheimer’s disease,” Neuron, vol. 112, no. 8, pp. 1208–1221, Apr. 2024.

[28] S. Raghavan et al., “Diffusion models reveal white matter microstructural changes with ageing, pathology and cognition,” Brain Commun., vol. 3, no. 2, p. fcab106, May 2021.

[29] E. Özarslan et al., “Mean Apparent Propagator (MAP) MRI: a novel diffusion imaging method for mapping tissue microstructure,” NeuroImage, vol. 78, pp. 16–32, Sep. 2013.

Authorized licensed use limited to: OAKLAND UNIVERSITY. Downloaded on February 15,2026 at 22:22:28 UTC from IEEE Xplore. Restrictions apply.